

SureFil^{SDR} flow ADVANCED CHEMISTRY. AMAZING PROCEDURES!
 POSTERIOR BULK FILL FLOWABLE BASE Changing the way you do posterior restorations

SEARCH



Login | Subscribe | Contact Us



Compendium Of Continuing Education In Dentistry

Share:

July/August 2011, Volume 32, Issue 6

Published by AEGIS Communications

Fiber-Reinforced Composites as a Fixed Space Maintainer in Case of Primary Tooth Loss

Sonu Acharya, BDS, MDS; and Shobha Tandon, BDS, MDS

Restorative dentistry is continually changing, with ground-breaking treatments developing based on new materials, techniques, and technologies. Composite materials are a leading example, and the introduction of fiber reinforcement has further increased the possible uses of composites in restorative dentistry. Maintaining arch length during primary, mixed, and early permanent dentition is essential for the development of occlusion. In an effort to prevent future problems, appliances may be placed to retain space resulting from early loss of teeth. In case of primary teeth loss, fixed space maintainers are being used, but these are time consuming to fabricate, and incorporated wires may lead to soft tissue trauma. This clinical case uses fiber-reinforced composite as a space maintainer, thus reducing the time required to complete treatment.

In spite of best efforts of practicing dentists, there still remains a large percentage of the population who do not present for treatment, except with pain or other condition. Unfortunately some of those individuals are children, who are not in a position to make the difficult decision to visit the dentist independently. Often by the time they are examined, there is no chance of saving the involved tooth, necessitating extraction and space maintenance.

To prevent closure of space and arch length deficiency, appliances may be placed to retain space. Different appliances may be used for space maintenance, such as the removable and fixed space maintainers, but they are difficult and time consuming to construct. Also, the attention span of a child patient is insufficient for this treatment protocol. Considering these difficulties, the clinician could choose the option of a space maintainer, which is less time consuming to fabricate, and for which patient acceptance is optimal.

Case Report

A 4-year-old child presented to the authors' clinic with the complaint of a missing posterior tooth. He had a history of extraction of a primary first deciduous molar 6 months before the visit. The child was provided with a functional removable space maintainer after extraction, however he did not wear it for long. The parents wanted a fixed appliance to be provided so that the child could not remove it on his own, however they were opposed to any appliance with wires, as they thought it might injure their child.

After thorough examination and discussion of the case, the authors concluded that space maintenance with fiber-reinforced composites was the best option. After explaining the prognosis for this appliance to the parents and some discussion, the parents agreed.

The child had worn an appliance earlier, so at the time there was no loss of space (Figure 1). After proper isolation of the area, the authors etched both the primary canine and second primary molar (Figure 2). These teeth were thoroughly dried and then bonding agent was applied (Figure 3).

After curing (Figure 4), the fiber-reinforced composite (Ribbond®, www.ribbon.com) was applied (Figure 5 and Figure 6). This material must be light cured. Occlusion was checked and found to be appropriate. The parents of the child were asked to report next day for follow-up and minor adjustments if required.

Discussion

This was an unusual case with a successful result. The authors have followed up for 8 months and the appliance is still present. Fiber-reinforced composites have been used in many situations with great success: periodontal splinting,¹ bridges,² and post-and-core.³ Use of fiber-reinforced composites for fixed space maintainers has been effective.⁴ In this article, the authors have attempted to provide practicing dentists with a novel idea that is acceptable to younger patients, as well as their parents.

Conclusion

Despite no long-term success rate being reported on this kind of appliance, the authors believe that

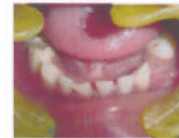

Figure 1

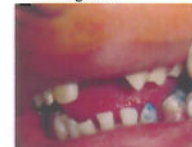

Figure 2

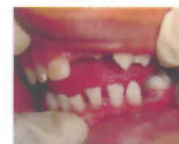

Figure 3

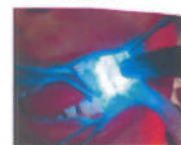



Figure 4

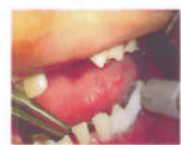

Figure 5

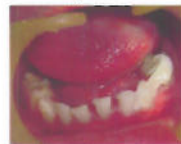

Figure 6



Select an issue

SUBSCRIBE TODAY!

Select a link below to view additional publications.

- Inside Dentistry
- Inside Dental Assisting
- Inside Dental
- Technology
- Online Only
- Special Issues +
- Whitepapers

EXGITE F Ivoclar Vivadent® Inc.



this appliance may be more suitable in certain cases than other fixed appliances (such as band and loop). Long-term follow-up will be necessary to arrive at the prognosis.

About the Authors

Sonu Acharya Assistant Professor
Department of Pediatric Dentistry
Institute of Dental Sciences
Bhubaneswar, Orissa, India

Shobha Tandon Professor
Department of Pediatric Dentistry
Dean
Manipal College of Dental Sciences
Manipal, Karnataka, India

References

1. Fowler EB, Breault LG. Esthetic periodontal splint with Ribbond. *Army Medical Department Journal*. 1994;Jan/Feb/Mar:52-55.
2. Strassler HE, Brown C. Periodontal splinting with a thin high-modulus polyethylene ribbon. *Compend Contin Educ Dent*. 2001;22(8):696-704.
3. Hornbrook DS, Hastings JH. Use of bondable reinforcement fiber for post and core build-up in an endodontically treated tooth: maximizing strength and aesthetics. *Pract Periodontics Aesthet Dent*. 1995;7(5):33-44.
4. Chafaie A, Fakhouri M. Collage et mainteneurs d'espace fixes en odontologie pediatrique. *Revue Dentaire Libanaise*. 1998;31:31-37.

Share this:

[BACK TO TOP](#)

© 2011 AEGIS Communications | [Contact Us](#) | [Terms of Service](#) | [Privacy Statement](#)