

Reconstruction of Nonvital Teeth Using Direct Fiber-reinforced Composite Resin: A Pilot Clinical Study

Simone Deliperi^a / David N. Bardwell^b

Purpose: To evaluate the clinical performance of direct Class II fiber-reinforced composite restorations on nonvital teeth.

Materials and Methods: Thirty patients age 18 or older were included in this clinical trial restoring 35 molars. The inclusion criteria were: two- to four-surface restorations, replacement of composite and amalgam restorations necessary or unrestored teeth with decay reaching the pulp, teeth having homogeneous root canal fillings terminating 0 to 2 mm from the radiographic apex. Teeth with residual cavity walls less than 1 mm or with complete loss of the clinical crown were excluded. Teeth were restored using a combination of Ultra etch 35% phosphoric acid, PQ1 adhesive system, and Vit-I-escence microhybrid composite resin. The enamel peripheral shell of the restoration was built up first; a resin-impregnated piece of polyethylene ribbon fiber (Ribbond Triaxial) was covered with B1 Perma-Flo flowable composite, placed into a prepared canal, folded, and light cured; then, dentin and enamel occlusal surface stratification was completed. All 35 restorations were evaluated at 6 months and 1 year by two independent evaluators using modified USPHS criteria.

Results: No failure was reported and alpha scores were recorded for all parameters. Before starting the treatment, 26 out of 35 teeth (74%) had apical periodontitis as diagnosed radiographically. At the 1-year recall, no signs of periapical lesions were detected and radiographs reported neither periodontal ligament widening nor periapical radiolucency.

Conclusion: Direct fiber-reinforced composite resin restorations demonstrated excellent clinical performance at 1 year.

Keywords: adhesive system, composite resin, Class II restoration, nonvital teeth, post and core, UHMWPE fiber, clinical report.

J Adhes Dent 2008; 10: xxxx-xxxx.

Submitted for publication: 01.04.07; accepted for publication: 14.11.07.

Nonrestored nonvital teeth are structurally compromised and represent one of the greatest challenges for the clinician. More than 15 years ago, the restoration of endodontically treated teeth was automatically associated with a combination of prefabricated or custom made metallic post and cores and full crowns. Various post materials and designs have been introduced over the years; a considerable amount of sound coronal and radicular tooth structure was sacrificed, increasing risk of root perforation

or fracture.¹² However, recent motivation to protect and reinforce the remaining sound tooth structure, bolstered by the properties of modern adhesive systems,²² has encouraged clinicians to re-evaluate the dogma of traditional restorative dentistry. Looking for alternative methods to build up nonvital teeth has become increasingly popular. Adhesive restorations allow clinicians to create minimally invasive preparations, thus preserving sound tooth structure; interestingly, the continuous improvement of the physical and mechanical properties of resin bonded composite (RBC) has encouraged clinicians to progressively abandon amalgam.⁴ Moreover, patient demand for esthetic restorations and desire to preserve remaining sound tooth structure have increased dramatically. Lately, dentists have expanded clinical indications for direct RBC restorations.^{6,7,16} This situation may be further influenced by a patient's inability to afford the ideal indirect restora-

^a Adjunct Assistant Professor, Tufts University School of Dental Medicine, Boston, MA, USA, and Private Practice, Cagliari, Italy.

^b Associate Clinical Professor of Restorative Dentistry, Tufts University School of Dental Medicine, Boston, MA, USA.

Correspondence: Dr. Simone Deliperi, Via G. Baccelli, 10/b, 09126 Cagliari-Italy. Tel: +39-347-953-3259, Fax: +39-070-302-588. e-mail: simone.deliperi@tufts.edu

tion in large posterior and anterior situations. As a consequence, clinical indications for anterior and posterior RBC restorations are progressively increasing.

Prefabricated tooth-colored fiber-reinforced composite (FRC) posts were introduced in the 1990s and have several advantages over conventional metal posts.²⁰ They are esthetic, bond to tooth structure, have a modulus of elasticity similar to that of dentin, but still require dentin preparation for canal placement.

Presently, alternative fiber reinforcement systems have been introduced in the attempt to increase RBC durability and damage tolerance;²³ Ultra High Molecular Weight Polyethylene (UHMWPE) fiber reinforcement systems are gaining popularity. Success is enhanced by utilizing bondable reinforcement fibers to build up endo posts and cores and adapt to the root canal walls without requiring additional enlargement of the root canal. These woven fibers have a modulus of elasticity similar to that of dentin and are purposed to create a monoblock dentin-post-core system, allowing better distribution of forces along the root.¹⁹ Recently, improved UHMWPE fiber systems have been introduced onto the market (Ribbond Triaxial). They have greater strength properties than conventional UHMWPE fibers because of the unidirectional alignment of fibers with braided filaments inserted between.

Fiber-reinforced composite resins may be based on various fabric configurations. The types of reinforcement may consist of unidirectional fibers, UHMWPE biaxial or triaxial braided fibers, and UHMWPE leno-woven fibers. The unidirectional configuration provides significant enhancement of strength and stiffness in the fiber direction, but it has poor transverse properties, resulting in the tendency for longitudinal splitting and premature failure. Resin-rich areas may also result from the architecture modification during handling. Fiber orientation of biaxially braided material may also change after cutting and embedding in the composite when adapting to tooth contours. The fibers in the ribbon spread out and separate from each other, loosening the integrity of fabric architecture.

In the triaxial braid architecture, fibers are arranged in three directions: the axial yarns and the two braiding yarns oriented at predetermined sets of angles (such as approximately 30 and 45 degrees). Karbhari and Wang¹³ reported that the use of triaxial braids increases the flexural characteristic of composite resin and provides a high level of fatigue resistance by isolating and arresting cracks. They also reported that the maximum flexural stress of dentin was around 60% higher than that of the unreinforced composite resin; conversely, the same braided composite resin provided over 70% enhancement in maximum stress level. UHMWPE triaxial braided fibers can be cut and embedded in dental composites with no architectural alteration; the fiber yarns maintain their orientation and do not separate from each other when closely adapted to the contours of teeth.

The purpose of this study was to evaluate the clinical performance of direct fiber-reinforced composite restorations when a microhybrid composite resin was used to reconstruct severely damaged posterior endodontically treated teeth. We hypothesized that a 100% composite resin retention could be expected at the 6-month recall.

MATERIALS AND METHODS

Selection Criteria

Thirty patients 18 years of age or older were included in this pilot clinical trial to reconstruct 35 endodontically treated posterior teeth.

Only teeth meeting the following criteria were included in the study:

- MO, DO or MOD Class II restorations (2- to 4-surface restorations)
- replacement of amalgam or composite resin restorations necessary because of secondary decay, fracture of either the filling material or tooth structure associated with periapical lesions, or unrestored teeth with decay reaching the pulp
- teeth with one or two missing cusps
- teeth in occlusion and having proximal contact with the adjacent teeth
- molars

Patients with occlusal parafunction were not included in the study. Patients whose teeth showed severe internal discoloration (tetracycline stains, fluorosis), smokers, and either pregnant or nursing women were excluded from the study. Teeth having a remaining cavity wall thickness < 1 mm or with complete loss of the clinical crown were also excluded (Table 1). Furthermore, patients unable to attend recall and having a gingival index score greater than 1 were excluded from the study.

Only endodontically treated teeth (see below for description of treatment) having homogeneous root canal fillings terminating 0 to 2 mm from the radiographic apex and having homogeneous root fillings were included in the study. Conversely, nonvital teeth with root canal fillings terminating more than 2 mm from the radiographic apex were excluded.

Informed consent was obtained prior to commencement of the study. All subjects received dental prophylaxis 2 weeks prior to the start of the study. Teeth were restored no later than 2 weeks after we completed endodontic treatment.

Endodontic Treatment

A crown-down technique was used for instrumentation; a 5.25% solution of sodium hypochlorite was used between each instrument size. The prepared canals were coated with a eugenol-based root canal sealer (Pulp canal sealer, Kerr Sybron;). The vertical condensation technique was accomplished using heated gutta-percha (System B, Kerr Sybron) to completely fill the root canals. Teeth were temporized using a provisional restorative material (Cavit W, 3M ESPE; St. Paul, MN, USA).

Restorative Procedure

Teeth were restored no later than two weeks after completing endodontic treatment. A rubber-dam was placed and the cavity prepared in a very conservative manner, removing only decay and/or the existing restoration with a #245 (ISO #008) bur (Shofu Dental; San Marcos, CA, USA), rounding sharp angles with a #2 (ISO #010) and #4 bur

(ISO #014) (Shofu). No bevels were placed to the occlusal or gingival surfaces (Fig 1). Three to four millimeters of gutta-percha were removed from root canals (distal in mandibular and palatal in maxillary molars) to expose dentin and increase microretention for the enamel/dentin adhesive systems. A sectional matrix (Composi-Tight, GDS; Spring Lake, MI, USA) was placed on the tooth and interproximal adaptation was secured using wooden wedges (Fig 2). Enamel and dentin were etched for 30 s using 35% phosphoric acid (Ultra Etch, Ultradent; South Jordan, UT, USA) (Fig 3); the etchant was removed and the cavity water sprayed for 30 s, being careful to maintain a moist surface. A fifth generation 40% filled ethanol-based adhesive system (PQ1, Ultradent) was placed in the preparation, gently air thinned to evaporate solvent, and light cured for 20 s at 800 mW/cm² from the occlusal surface using an LED curing light (Ultra-Lume V, Ultradent) (Fig 4).

In order to avoid microcrack formation on the remaining facial/palatal wall, the authors used a previously described technique, which is based on a combination of pulse and progressive curing technique^{5,7} (Table 2).

A particular composite placement technique was also selected to build up the restorations. Vit-I-escence microhybrid RBC (Ultradent) was considered the material of choice to restore the nonvital teeth because of its variety of enamel shades and excellent mechanical properties.⁷ The sectional matrix was burnished against the adjacent teeth. Tooth buildup was started using 2-mm wedge-shaped, gingivo-occlusally placed layers of amber (PA) and smoke (PS) enamel shades to reconstruct the proximal and palatal surfaces. This uncured composite was condensed and sculptured against the cavosurface margins and sectional matrix; each increment was pulse cured for 3 s at 800 mW/cm² to avoid microcrack formation. Final polymerization of the PA and PS composite proximal and palatal/facial walls was then completed at 800 mW/cm² for 20 s. The enamel peripheral skeleton of the restoration was built up, providing more spatial references to create a correct occlusal anatomy (Fig 5). A UHMWPE triaxial fiber (Ribbond; Seattle, WA, USA) was selected and manipulated according to manufacturer's instructions. Triaxial fibers were wetted with an unfilled resin (Permaseal, Ultradent), resin excess was removed, the fibers completely covered with a B1 light-cureing flowable composite resin (Permaflo, Ultradent) and placed in the central area of the restoration. UHMWPE triaxial fibers were folded and each end pushed in the root canal using a thin composite spatula⁶ (Fig 6). The fiber-resin complex and flowable composite resin were light cured at 800 mW/cm² for 120 s to assure complete polymerization of the fiber-composite resin complex down into the canal. Dentin stratification of the facial, palatal, and proximal walls was initiated, placing 2-mm wedge-shaped increments of A3 RBC onto each enamel wall, avoiding contact with fresh increments. Successive A4 and A3.5 increments were placed in the central area of the restoration, surrounding the resin-impregnated fiber-composite system to increase the chroma, unnaturally reduced by previously using B1 flowable composite; a direct post and core was created. Each dentin increment was cured using a progressive "curing through"

Table 1 Main characteristics of the cavity preparation before final restoration

Patient	Tooth #	Missing cusp	Ribbond placement (canal)	Existing previous restoration	Decay	Missing marginal ridge	No. Of involved surfaces
1	46	-	D	A	+	M-D	3
2	36	MF	D	A	+	M	3
3	16	MF	MF	C	+	M	3
4	16	MP	P	A	+	M	3
	47	ML	D	A	-	M	
5	47	DL	D	-	+	D	3
6	37	ML DL	D	C	+	M	4
7	26	-	P	-	+	M	2
8	46	DL	D	A	-	D	3
9	26	P	P	A		M-D	3
10	26	DP	P	A		D	3
11	46	-	D	A	-	M-D	3
12	36	DL	D	A	+	D	3
13	46	MF	D	A	-	M	3
14	27	MP	P	A	+	M	3
15	46	DV	D	A	+	M-D	4
16	47	ML	D	A	+	M	3
	37	MF	D	A	+	M	3
	16	DP	P	A	-	D	3
17	26	MF	P	A	+	M	3
18	36	DL	D	A	+	D	3
19	27	DP	P	C	-	D	3
20	16	DP DF	D	A	-	D	4
21	36	DL	D	C	+	D	3
22	26	DP	P	A	-	D	3
23	26	DP	P	C	+	D	3
24	27	-	P	A	-	M-D	3
25	47	-	M	C	-	D	2
26	26	-	P	A	-	M-D	3
27	46	ML	D	A	+	M	3
	36	MF	D	A	+	M	3
28	37	DL	D	C	+	D	3
	16	DP	P	-	-	D	3
29	17	MP	P	-	+	M	3
30	36	-	D	A	+	M-D	3

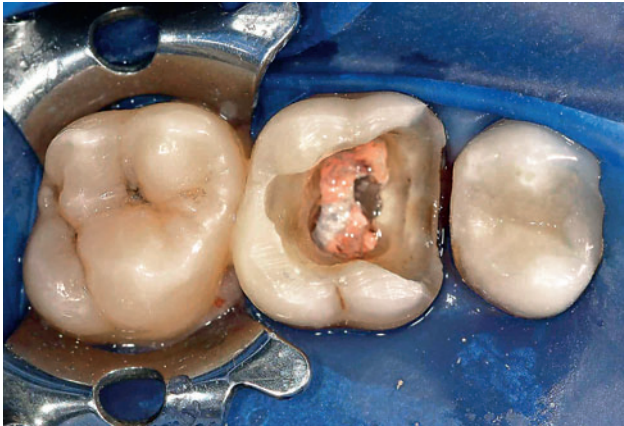

Fig 1 Occlusal view of tooth 26 after placing rubber-dam, preparing cavity, and removing provisional restoration.

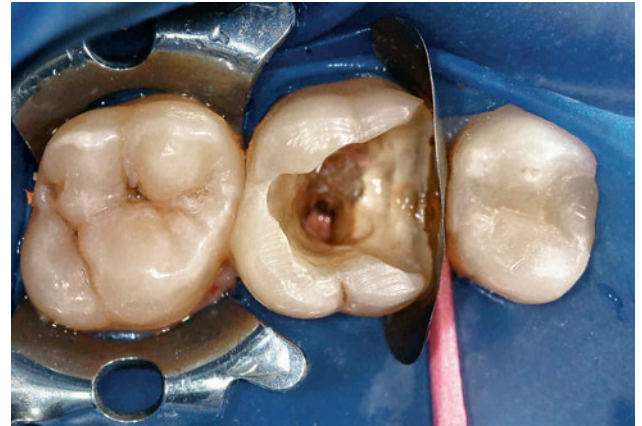

Fig 2 Three to 4 mm of gutta-percha were removed from the palatal root canal and a sectional matrix was placed.

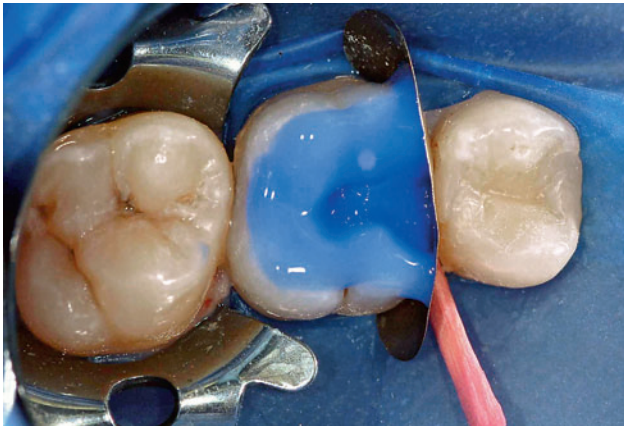


Fig 3 Etching was performed using 35% phosphoric acid.

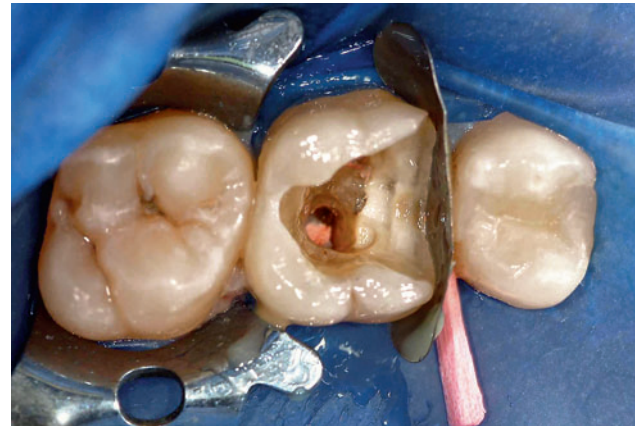

Fig 4 A filled ethanol-based adhesive system was applied on both enamel and dentin.

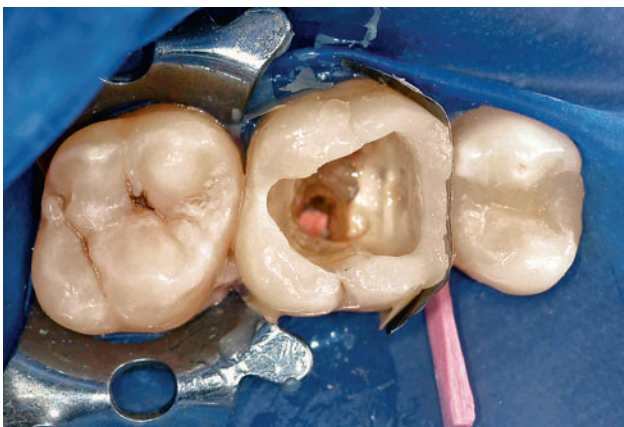

Fig 5 The peripheral enamel skeleton was built up using wedge-shaped increments of PA and PS shades.

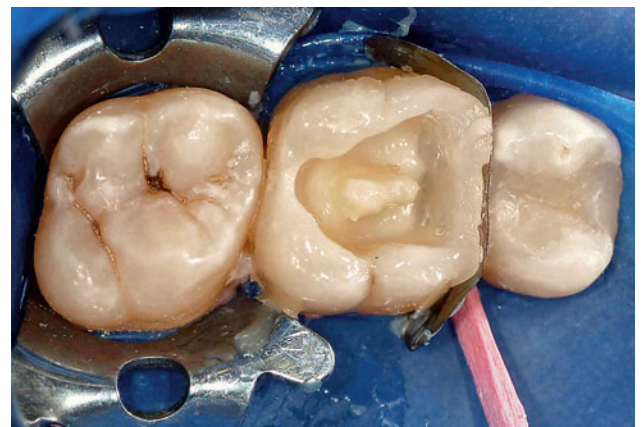

Fig 6 A piece of Ribbond fiber was wetted with unfilled resin, covered with flowable composite and inserted into the palatal canal.

Table 2 Recommended photocuring times and intensities for enamel, dentin, and post-and-core buildup

Buildup	Composite shade	Polymerization technique	Intensity (mW/cm ²)	Time (seconds)
Proximal and palatal enamel	PA/PS	Pulse	800 + 800	3 + 20
Ribbon post-and-core buildup	B1	Progressive curing	800	120
Dentin	A4 to A1	Progressive curing and continuous curing	800	20* +20
Occlusal enamel	PN/PF	Pulse	800 + 800	1 + 20**

* Curing through, **20 per each surface (palatal, facial and occlusal surface)

technique (40 s at 800 mW/cm² through the facial and lingual walls instead of a conventional continuous irradiation mode of 20 s at 800 mW/cm² from the occlusal surface). At this point, the middle third of the dentin restoration was built up using a combination of A2 and A1 composite resin (Fig 7). Enamel layers of PF or PN were applied to the final contour of the occlusal surface according to a successive cusp buildup technique (Fig 8). This final layer was pulse cured for 1 s at 800 mW/cm². A waiting period of 3 min was observed to allow for stress relief; wedges and matrix were removed as well as the rubberdam, occlusion was checked, and the restoration was finished using the Ultradent Composite Finishing Kit. The final polymerization cycle was completed by irradiating the restored tooth through the facial, palatal, and occlusal surfaces for 20 s each at 800 mW/cm². Final polishing was performed using Jiffy polishing cups and points (Finale, Ultradent) (Fig 9).

Follow-up Procedures

Three expert investigators were involved: the first investigator restored the teeth, and restorations were evaluated by two investigators pre-calibrated at 85% reliability. Disagreement was resolved with a consensus. A periapical radiograph was taken of each tooth at baseline, after completing the root canal restoration, and at the 1-year recall (Fig 10). A Super-Bite Kerr-Hawe holder (Kerr-Hawe; Bioggio, Switzerland) and a Ultra Speed Kodak film (Kodak; Rochester, NY, USA) were used according to a paralleling technique.

Restorations were evaluated after 6 months and one year using modified USPHS criteria by two independent evaluators; USPHS criteria were adjusted to test direct fiber-reinforced restorations by including post, root canal, and periapically related factors (Table 3). Pictures were taken at each recall (Fig 11).

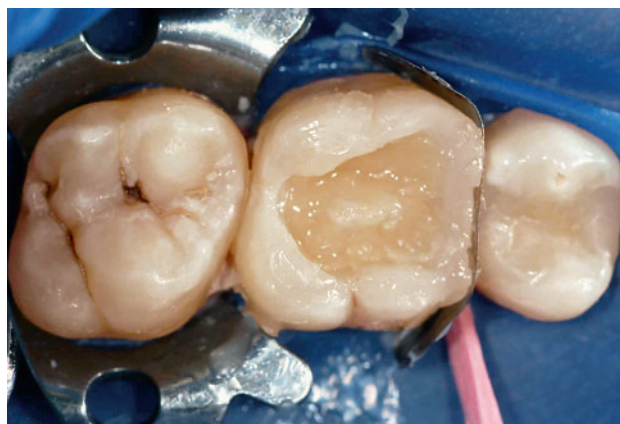

Fig 7 Dentin stratification was performed placing A4 to A1 shades.

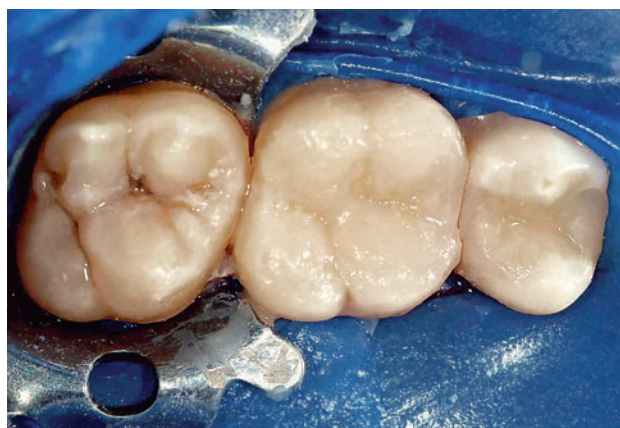

Fig 8 Restoration was completed with the application of PF/PN shade to the final contour of the occlusal surface.

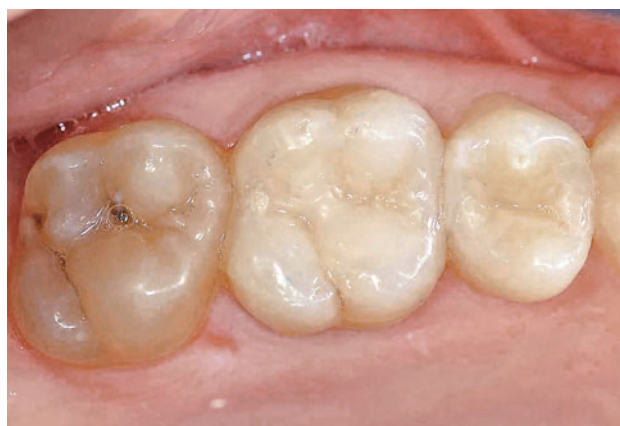

Fig 9 Postoperative occlusal view of the final restoration following endodontic and restorative treatments.

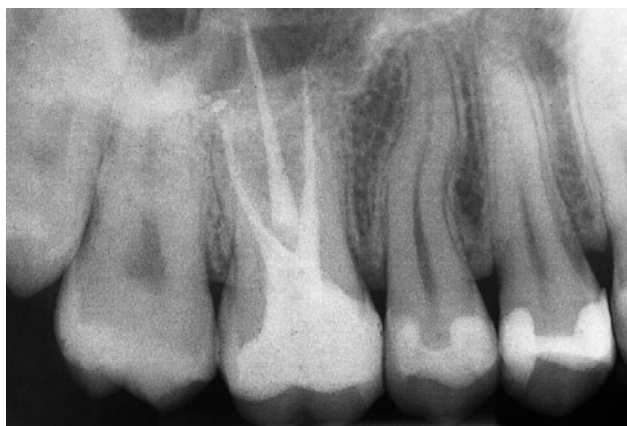

Fig 10 Radiographic image of tooth 26 at the one-year recall.

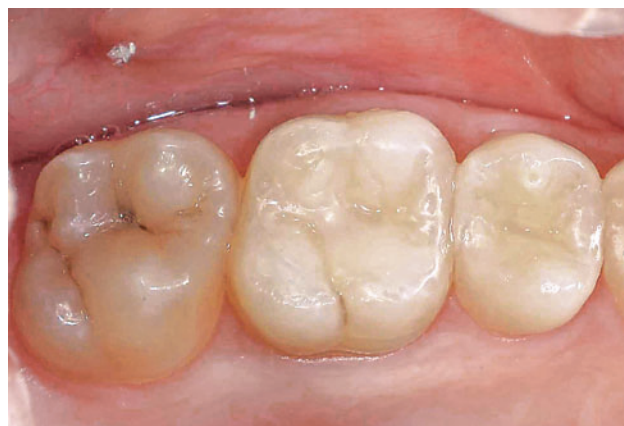

Fig 11 Clinical image of tooth 26 at the one-year recall.

Table 3 Modified USPHS criteria used for direct clinical evaluation of the restorations (extended for direct fiber post restorations)

Score	Alpha	Bravo	Charlie	Delta
Surface texture	Sound	Rough	-	-
Anatomical form	Sound	Slight loss of material (chipping, clefts), superficial	Strong loss of material (chipping, clefts), profound	Total or partial loss of the bulk
Marginal integrity (enamel)	Sound	Positive step, removable by finishing	Slight negative step not removable, localized	Strong negative step in major parts of the margin, not removable
Marginal discoloration (enamel)	None	Slight discoloration, removable by finishing	Discoloration, localized not removable	Strong discoloration in major parts of the margin not removable
Secondary caries	None	Caries present	-	-
Gingival inflammation	None	Slight	Moderate	Severe
Restoration color stability	No change	Change of color comparing to baseline condition	-	-
Post	In situ with no gap between post and gutta-percha or post and cavity walls	Gap between post and gutta-percha or post and cavity walls	Post displacement or detachment	Post fracture
Root	No clinical or radiographic sign of root fracture	Root fracture, with bone loss next to the root surface and pain on biting	-	-
Periapical status	Normal: good periapical condition	Widening of the periodontal ligament (PL) not exceeding twice the width of the lateral PL	Periapical radiolucency in connection with the apical part of the root, exceeding at least twice the width of the lateral PL	-

RESULTS

All patients returned for composite resin restoration re-evaluation at the 1-year recall. No failures were recorded, and alpha scores were documented for all parameters, both coronal and radicular.

Before starting the treatment, 26 out of 35 teeth (74%) had apical periodontitis as diagnosed radiographically. At the 1-year recall, no signs of periapical lesions were detected and radiographs showed neither periodontal ligament widening nor periapical radiolucency.

DISCUSSION

Metal posts do not strengthen endodontically treated teeth, and their use is justified only for retention of the coronal restoration.²⁵ Post preparation may be responsible for the destruction of sound tooth structure along with the risk of root perforation.

Direct UHMWPE triaxial fiber posts may represent a valid alternative to conventional metal and pre-fabricated fiber posts; indeed, UHMWPE fiber posts may have some advantages over conventional prefabricated FRC posts. They are used as direct esthetic custom posts; they adapt to the root canal walls without requiring additional enlargement of the root canal after endodontic treatment on both regular and flared orifices.

Interestingly, no radiographic signs of post displacement or detachment were detected during the observation period. This short-term clinical success may be related to the adopted post adhesive cementation technique and the UHMWPE triaxial fiber structure. Details of selecting a particular cementation protocol have been published previously;⁶ the combination of a visible light-curing unfilled resin and flowable composite to bond the woven fibers to the tooth structure and composite resin core represents a valid alternative to conventional cementation techniques. Prefabricated FRC posts consist of reinforcing fibers embedded in a highly cross-linked polymer matrix.¹⁷ The monomers of the composite resin luting cement cannot penetrate into the fibers; the bond strength relies on the micromechanical bonding between the prefabricated post surface and luting agent. Conversely, a free radical polymerization of the flowable composite to the resin embedded woven fibers is expected using custom UHMWPE FRC posts.

It can be argued that complete polymerization of the fiber-composite resin complex down into the canal may be compromised using the curing technique adopted in this study. However, only 3 to 4 mm of gutta-percha were removed from the root canal, a curing cycle of 120 s at 800 mW/cm² was completed to assure complete polymerization, and further light energy was provided during the core build up and final polymerization procedure. Moreover, increased composite resin photosensitivity and LED curing light technology may help to achieve this goal.²⁴ Lindberg et al¹⁸ compared the depth of cure of quartz-tungsten-halogen (QTH) and LED curing units at different exposure times and light tip to resin composite distances. The authors used 6 mm specimens of A3 composite resin. Despite lower power density of the LED unit (Ultralume 2), similar depths of cure were reported for the 20- and 40-s exposure times at a 0, 3 and 6 mm distance using both QTH and LED curing units. These findings were explained by the fact that QTH power density includes spectral ranges that are not well absorbed by camphoroquinone. Yap and Soh²⁷ reported that new generation high power LED lamps may cure composite resin as effectively as conventional QTH/LED lights with a 50% reduction in curing time. Ernst and colleagues⁸ compared the depth of cure of different QTH and LED curing units. One- to 5-mm thick A3 composite resin samples were used and the light-guide tip was kept 7 mm from the bottom side of the composite specimen. The authors observed that LED curing

devices are capable of curing composite resin as well as or even better than high intensity QTH curing devices. It is noteworthy that we selected a lighter composite resin shade (B1) to cement the UHMWPE fiber-reinforced posts into the canal in our study. We also used an LED curing device with higher intensity compared to those adopted in other laboratory studies.^{8,18,27}

In this study, post-endodontic reconstructions were evaluated. It was paramount to distinguish between apical periodontitis due to endodontic treatment failure vs that due to post-coronal filling failure. During evaluator calibration, a consensus was achieved regarding the origin of periapical lesions. Apical radiolucency associated with post displacement or detachment was related to coronal restoration failure; conversely, failure was related to endodontic treatment when incomplete periapical healing was detected in the absence of any post displacement or detachment. Interestingly, the periapical health of nonvital teeth was related to the quality of the coronal restoration. Inadequate root canal treatment and coronoradicular posts were reported to be associated with increased prevalence of periapical radiolucency.¹⁴ Ray and Trope²¹ reported that the quality of the coronal restoration may be of greater importance for the periapical status than the quality of endodontic treatment. Tronstad and co-workers²⁶ reported opposite findings. It bears mentioning, however, that periapical healing evaluation is an adjunctive means to assess the performance of fiber-reinforced composite restorations and reduce bias. We included the "periapical healing" parameter in the standard USPHS criteria.

Resin-impregnated polyethylene ribbon fiber systems were placed into prepared canals and used as post systems. Post dislodgement or fracture may increase coronal leakage, thus influencing the periapical status. The combination of appropriate endodontic and restorative treatments may explain the disappearance of apical radiolucency in this study, in agreement with previous clinical observations.^{21,26} Variables were reduced by selecting endodontically treated teeth having root canal fillings terminating 0 to 2 mm from the radiographic apex and having homogeneous root fillings. In this context, periapical healing was more likely to occur.

A combination of RBC wedge-shaped increments and UHMWPE fiber reinforcement system (Ribbond Triaxial) was considered of paramount importance to further reduce polymerization shrinkage, better support the RBC, reinforce the remaining tooth structure, and reduce total composite volume.^{1-3,13} An increased C-factor may result as a consequence of building up the restoration enamel contour first. The C-factor is defined as the ratio between bonded and unbonded surfaces; increasing this ratio resulted in increased polymerization stresses.⁹ In this context, the application of wedge-shaped increments of composite resin was essential, because it helped decrease the C-factor.

UHMWPE fiber-reinforced posts may contribute to the retention of RBC restorations; further clinical investigations should compare direct fiber-reinforced RBC restorations with post-free direct RBC restorations to assess the potential increased retention and strength produced by woven fibers on compromised, nonvital teeth. The com-

bined effect of favorable fiber modulus and the intrinsic fabric architecture, ie, fibers oriented in multiple directions, allows for the force to be distributed over a wider area, thereby decreasing stress levels.³ Previous laboratory studies reported that UHMWPE fibers in conjunction with flowable composite resin increased the fracture strength of nonvital molars with MOD cavity preparations.^{1,2}

Although the observation time is limited to only 1 year, the results of this clinical study are encouraging. Marginal integrity, anatomical form, and texture were preserved over a one-year follow-up period. No marginal discoloration, recurrent decay, chipping, or composite clefts were detected. Interestingly, 28 out of 35 teeth had restorations with at least one cusp involved. Previous laboratory studies on cusp-replacing RBC indicated that the tooth/restoration interface failure was more probable than composite material failure.^{10,11} These findings suggest that both physical and mechanical properties of composite resins have dramatically improved in the last decade.¹⁵

Neither long- nor short-term studies have followed up the clinical performance of direct fiber-reinforced RBC restorations on nonvital compromised teeth. The latter have been considered an interim restoration for teeth with questionable prognosis. Placement has been reserved for patients with financial limitations or compromised medical histories.⁶ Minimal sacrifice of sound tooth structure is required when selecting RBC restorations, even in severely damaged teeth; cusps with 1 to 1.5 mm remaining enamel-dentin thickness were preserved in this study.

No retention or resistance forms were included in the cavity preparation; RBC restoration retention relied only on the adhesion of the composite resin to tooth structure and the bondable UHMWPE fiber-reinforced post. The use of modern adhesive systems and composite resins may be able to reinforce residual tooth structure. Further clinical evaluation is required to assess the durability of the composite bond to both enamel and dentin over time in similar scenarios; both direct and indirect restorations requiring an adhesive cementation protocol should be examined.

CONCLUSION

Although compromised nonvital molars were restored in this study, the direct fiber-reinforced composite resin restorations demonstrated excellent clinical performance after 1 year. A positive relationship between adequate coronal-radicular filling and periapical healing was observed. However, further independent controlled clinical observations are necessary to validate this outcome over a longer period.

ACKNOWLEDGMENTS

The authors would like to express their gratitude to Ribbond and Ultradent Inc. for providing all necessary materials.

REFERENCES

1. Belli S, Erdemir A, Ozcopur M, Eskitascioglu G. The effect of fibre insertion on fracture resistance of root filled molar teeth with MOD preparations restored with composite. *Int Endod J* 2005;38:73-80.

2. Belli S, Erdemir A, Yildirim C. Reinforcement effect of polyethylene fibre in root-filled teeth: comparison of two restoration techniques. *Int Endod J* 2006;39:136-42.
3. Belli S, Cobankara FK, Eraslan O, Eskitascioglu G, Karbhari V. The effect of fiber insertion on fracture resistance of endodontically treated molars with MOD cavity and reattached fractured lingual cusps. *J Biomed Mater Res B Appl Biomater* 2006;79:35-41.
4. Christensen GJ. Amalgam vs. composite resin. *J Am Dent Assoc* 1998;129:1757-1759.
5. Deliperi S, Bardwell DN. An alternative method to reduce polymerization shrinkage in direct posterior composite restorations. *J Am Dent Assoc* 2002;133:1387-1398.
6. Deliperi S, Bardwell DN, Coiana C. Reconstruction of devital teeth using direct fiber-reinforced composite resins: a case report. *J Adhes Dent* 2005;7:165-171.
7. Deliperi S, Bardwell DN. Clinical evaluation of cuspal coverage direct posterior composite resin restorations. *J Esthet Rest Dent* 2006;18:256-267.
8. Ernst CP, Meyer GR, Muller J, Stender E, Ahlers MO, Willershausen B. Depth of cure of LED vs QTH light-curing devices at a distance of 7 mm. *J Adhes Dent* 2004;6:141-150.
9. Feilzer AJ, De Gee AJ, Davidson CL. Setting stress in composite resin in relation to configuration of the restoration. *J Dent Res* 1987;66:1636-1639.
10. Fennis WM, Kuijs RH, Kreulen CM, Verdonshot N, Creugers NH. Fatigue resistance of teeth restored with cuspal-coverage composite restorations. *Int J Prosthodont* 2004;17:313-317.
11. Fennis WM, Kuijs RH, Barink M, Kreulen CM, Verdonshot N, Creugers NH. Can internal stresses explain the fracture resistance of cusp-replacing composite restorations? *Eur J Oral Sci* 2005;113:443-448.
12. Fuss Z, Lustig J, Katz A, Tamse A. An evaluation of endodontically treated vertical root fractured teeth: impact of operative procedures. *J Endod* 2001;27:46-48.
13. Karbhari VM, Wang Q. Influence of triaxial braid denier on ribbon-based fiber reinforced dental composites. *Dent Mater* 2007;23:969-976.
14. Kirkevang LL, Orstavik D, Horsted-Bindslev P, Wenzel A. Periapical status and quality of root fillings and coronal restorations in a Danish population. *Int Endod J* 2000;33:509-511.
15. Kuijs RH, Fennis WM, Kreulen CM, Barink M, Verdonshot N. Does layering minimize shrinkage stresses in composite restorations? *J Dent Res* 2003;82:967-971.
16. Kuijs RH, Fennis WM, Kreulen CM, Roeters FJ, Creugers NH, Burgersdijk RC. A randomized clinical trial of cusp-replacing resin composite restorations: efficiency and short-term effectiveness. *Int J Prosthodont* 2006;19:349-354.
17. Le Bell AM, Tanner J, Lassila LV, Kangasniemi I, Vallittu P. Bonding of composite resin luting cement to fiber-reinforced composite root canal posts. *J Adhes Dent* 2004;6:319-325.
18. Lindberg A, Peutzfeldt A, van Dijken JW. Effect of power density of curing unit, exposure duration, and light guide distance on composite depth of cure. *Clin Oral Investig* 2005;9:71-76.
19. Newman MP, Yaman P, Dennison J, Rafter M, Billy E. Fracture resistance of endodontically treated teeth restored with composite posts. *J Prosthet Dent* 2003;89:360-367.
20. Qualtrough AJE, Mannocci F. Tooth-colored post systems: a review. *Oper Dent* 2003;28:86-91.
21. Ray HA, Trope M. Periapical status of endodontically treated teeth in relation to the technical quality of the root filling and the coronal restoration. *Int Endod J* 1995;28:12-18.
22. Roeters JJ. Extended indications for directly bonded composite restorations: a clinician's view. *J Adhes Dent* 2001;3:81-87.
23. Rudo DN, Karbhari VM. Physical behaviors of fiber reinforcement as applied to tooth stabilization. *Dent Clin North Am* 1999;43:7-35.
24. Stansbury JW. Curing dental resins and composites by photopolymerization. *J Esthet Restor Dent* 2000;12:300-308.
25. Stockton L, Lavelle CLB, Suzuki M. Are posts mandatory for the restoration of endodontically treated teeth? *Endod Dent Traumatol* 1998;14:59-63.
26. Tronstad L, Asbjornsen K, Doving L, Pedersen I, Eriksen HM. Influence of coronal restorations on the periapical health of endodontically treated teeth. *Endod Dent Traumatol* 2000;16:218-221.
27. Yap AU, Soh MS. Curing efficacy of a new generation high-power LED lamp. *Oper Dent* 2005;30:758-763.

Clinical relevance: In selected clinical situations, direct fiber-reinforced posterior composite restorations may represent a valid alternative to conventional indirect restorations.